

From the Department of Ophthalmology, Yamaguchi University Graduate School of Medicine, Ube City, Yamaguchi, Japan. E-mail: k.fukuda@yamaguchi-u.ac.jp.

Disclosure of potential conflict of interest: The authors have declared that they have no conflict of interest.

REFERENCES

1. Kumagai N, Fukuda K, Fujitsu Y, Seki K, Nishida T. Treatment of corneal lesions in individuals with vernal keratoconjunctivitis. *Allergol Int* 2005;54:51-9.
2. Fukushima A, Ozaki A, Fukata K, Ishida W, Ueno H. Ag-specific recognition, activation, and effector function of T cells in the conjunctiva with experimental immune-mediated blepharoconjunctivitis. *Invest Ophthalmol Vis Sci* 2003;44:4366-74.
3. Magone MT, Chan CC, Rizzo LV, Kozhich AT, Whitcup SM. A novel murine model of allergic conjunctivitis. *Clin Immunol Immunopathol* 1998;87:75-84.
4. Trocmé SD, Gleich GJ, Kephart GM, Zieske JD. Eosinophil granule major basic protein inhibition of corneal epithelial wound healing. *Invest Ophthalmol Vis Sci* 1994;35:3051-6.
5. Kumagai N, Fukuda K, Ishimura Y, Nishida T. Synergistic induction of eotaxin expression in human keratocytes by TNF- α and IL-4 or IL-13. *Invest Ophthalmol Vis Sci* 2000;41:1448-53.
6. Fukuda K, Fujitsu Y, Seki K, Kumagai N, Nishida T. Differential expression of thymus- and activation-regulated chemokine (CCL17) and macrophage-derived chemokine (CCL22) by human fibroblasts from cornea, skin, and lung. *J Allergy Clin Immunol* 2003;111:520-6.
7. Kumagai N, Fukuda K, Fujitsu Y, Yamamoto K, Nishida T. Role of structural cells of the cornea and conjunctiva in the pathogenesis of vernal keratoconjunctivitis. *Prog Retin Eye Res* 2006;25:165-87.
8. Garcia-Zepeda EA, Rothenberg ME, Ownbey RT, Celestin J, Leder P, Luster AD. Human eotaxin is a specific chemoattractant for eosinophil cells and provides a new mechanism to explain tissue eosinophilia. *Nat Med* 1996;2:449-56.
9. Imai T, Baba M, Nishimura M, Kakizaki M, Takagi S, Yoshie O. The T cell-directed CC chemokine TARC is a highly specific biological ligand for CC chemokine receptor 4. *J Biol Chem* 1997;272:15036-42.

doi:10.1016/j.jaci.2009.10.041

Nasal inflammation in vernal keratoconjunctivitis

To the Editor:

Vernal keratoconjunctivitis (VKC) is a bilateral ocular disease characterized by chronic inflammation of the whole conjunctiva with variable corneal involvement.¹ Conjunctival "cobblestone papillae" are a characteristic of the disease; the cornea can develop punctate keratitis, erosions, shield ulcers, plaques, and neovascularization.^{1,2} VKC typically appears before the age of 10 years and tends to improve or remit in adulthood.³ The term *vernal* is largely accepted for historical reasons because VKC sometimes displays spring or autumn exacerbations that are followed by periods of remission. Nonetheless, the term is not completely appropriate, because many patients with VKC have exacerbations during winter or develop a perennial form of the disease. VKC might occur in people with a family history of atopy or with allergic sensitization, although the role allergy in the pathophysiology of VKC is unclear. Allergic rhinitis is commonly associated with conjunctivitis, and the term *rhinoconjunctivitis*⁴ is frequently used. We therefore studied the nasal characteristics of patients with VKC, to determine if the nasal mucosa is involved as in classic allergic rhinoconjunctivitis.

Consecutive outpatients, at their first diagnosis of VKC, were given an ear, nose, and throat examination before they were treated. The parents of pediatric patients signed an informed consent form, and the protocol was approved by the local ethical committee. The diagnosis of VKC was always made by an ophthalmologist. The presence of at least typical papillae or corneal involvement was required.⁵ The subjective severity was graded by patients >12 years (or by their parents) by scoring for each eye, from 0 (absent) to 3 (severe), for the following

features: ocular itching, foreign body sensation, photophobia, and watering. An objective score of values from 0 to 3 was assigned by the ophthalmologist to rate the following: hyperemia, tarsal/limbal papillae, neovascularization, and cornea ulceration. The family history of atopy was determined by asking parents about the presence of rhinitis and/or asthma and/or atopic dermatitis. The history of rhinitis symptoms was assessed according to the International Study on Allergy and Asthma in Childhood (ISAAC) questionnaire. Patients/parents recorded the instantaneous rhinitis symptoms, assigning scores of 0 to 3 for nasal itching, obstruction, rhinorrhea, and sneezing. All patients underwent skin prick tests and CAP-RAST, and levels of total IgE were assayed. Skin tests were performed with commercial extracts (Lofarma SpA, Milan, Italy) of house dust mites, grass, *Parietaria*, olive, cypress, birch, hazelnut, ragweed, and cat and dog dander. Nasal and conjunctival scrapings were collected for cytology analysis by using a RhinoProbe device (Cardinal Health, Dublin, Ohio) according to a validated methodology.^{6,7} Nasal smears were obtained from the middle portion of the inferior turbinate. Conjunctival scrapings were obtained from the middle portion of the inferior palpebra. At the time of evaluation, patients had not yet been treated for allergic symptoms (eg, with antihistamines, steroids, or mast-cell stabilizers). The smear samples were fixed, air dried, stained with May-Grünwald-Giemsa (Carlo Erba, Milan, Italy), and examined by light microscopy (at 1000-fold magnification using a Nikon E600; Nikon, Milan, Italy). Total numbers of cells, eosinophils, and mast cells were counted in 10 fields of each sample.⁷ Each specimen was examined by 2 blind investigators, and mean values were obtained. Correlations between parameters were calculated using the Pearson test.

Thirty-eight patients (30 boys; age range, 3-18 years) were studied; 13 subjects (34%) had atopy (1 or both parents had allergic hypersensitivity). Two subjects had asthma, and 8 had atopic dermatitis. Four patients (11%) tested positive to at least 1 allergen (cypress, grass, or olive), confirmed by the CAP-RAST, and 18 subjects had total IgE levels greater than 200 kU/L. A mild septal deviation was observed in 7 patients and a tonsil hypertrophy in 12. A clinical history of rhinitis was present in 15% of subjects. The rhinitis scores were 0 of 12 in 21 subjects and 4 of 12 or less in the remaining 17 patients. The conjunctival objective score assigned by the ophthalmologist was <6 in 6 patients and >10 in 12.

The mean total cell count in nasal samples was 23.8 ± 19 , including 18.4 ± 15 eosinophils (range, 0-60) and 4.9 ± 2 mast cells (range, 3-22). Nasal scrape samples were negative in 9 (23.6%) patients; samples from 10 patients (26.3%) contained only eosinophils, 5 (13.2%) had only mast cells, and 14 (36.9%) had a mixed inflammatory cell population (eosinophils and mast cells). Conjunctival scrape samples were abnormal in all subjects. The mean total cell count was 103.6 ± 44 (range, 22-165), with 54.8 ± 19 eosinophils (range, 22-118) and 48.1 ± 25 mast cells (range, 7-125). One subject had only eosinophils, 5 had only mast cells, and 32 (84.2%) subjects had a mixed cell population. The conjunctival total cell count correlated with the subjective ($r = 0.45$; $P = .04$) and objective ($r = 0.44$; $P = .04$) conjunctival scores (Fig 1). No correlation was found between nasal cell count and nasal score or between the nasal and conjunctival cell counts ($r = 0.02$; $P = .8$; Fig 1). Similar observations were made when eosinophils and mast cells were analyzed separately. A correlation between cell counts and skin sensitizations could not be determined because of the small number of patients with a positive

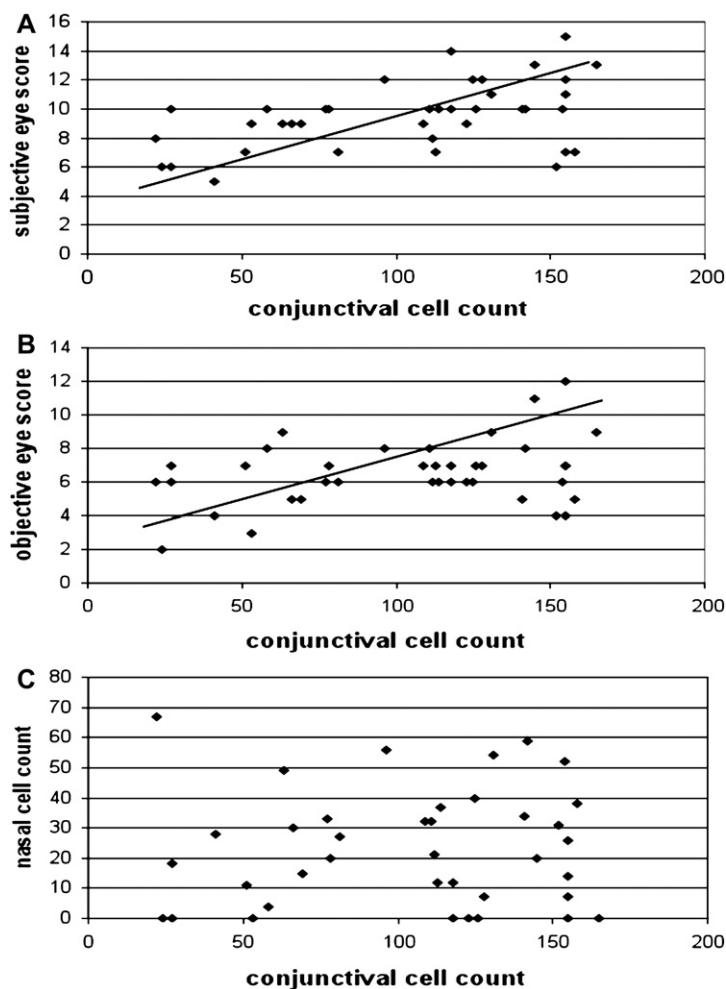


FIG 1. **A**, Correlation between the total cell count in conjunctival scrape samples and the objective conjunctival score. **B**, Correlation between the total cell count in conjunctival scrape samples and the subjective conjunctival score. **C**, Correlation between nasal and conjunctival cell counts.

skin test result. Finally, there was no correlation between cell counts and total levels of IgE.

Vernal keratoconjunctivitis is traditionally categorized as an ocular allergy, along with allergic and atopic conjunctivitis.⁸ This categorization is supported by VKC's association with atopy and the presence of IgE sensitization in 25% to 50% of patients.^{1,2} Immunology data indicate that a T_H2 -cell immune response is involved in its pathogenesis.^{9,10} Nonetheless, the role of atopy in VKC has not been proven clinically.¹ Seasonality and atopy have been observed in only a limited number of patients with VKC, and patients respond poorly to standard antiallergic treatments. Considering the close relationship between the nose and the eye in IgE-mediated allergies,⁴ we evaluated whether the VKC nasal mucosa was involved. In our case series, we confirmed the low prevalence of allergic sensitization, the predominance of the male sex (79%), and the frequent coexistence of atopic dermatitis (21%). Surprisingly, inflammatory cells were detected in the nasal mucosa, represented by eosinophils and mast cells. This nasal inflammation was independent of the allergic sensitization and was not accompanied by nasal symptoms, as commonly occurs in allergic rhinitis. Of note, the nasal inflammation was less intense in the nose than in the conjunctiva.

Nasal inflammation might therefore result from passage of the conjunctival cells through the nasolacrimal duct—this would explain the fact that there are fewer cells in the nose than in the eye. To test this hypothesis formally, the duct would have to be blocked, which is not feasible. The absence of a correlation between the nasal and conjunctival cell types weakens the hypothesis that conjunctival cells pass through the nasolacrimal duct. VKC might also involve a combination of the conjunctiva and the nose (eg, local IgE production). This is unlikely because of the almost complete absence of nasal symptoms in VKC, whereas in allergic rhinitis, symptoms usually parallel the level of inflammation.¹¹

This is the first description of nasal inflammation in patients with VKC. On the basis of available data, it is not possible to determine whether the nasal infiltration is a passive phenomenon or a true active inflammation; this aspect of VKC pathogenesis deserves more detailed investigations.

Matteo Gelardi, MD^a
Laura Spadavecchia, MD^b
Pietro Fanelli, MD^b
Maria Luisa Fiorella, MD^a
Cosimo Russo, MD^a

Raffaele Fiorella, MD^a
Lucio Armenio, MD^b
Giovanni Passalacqua, MD^c

From ^athe Department of Ophthalmology and Otolaryngology, Otolaryngology II, and ^bDipartimento di Biomedicina Dell'Età Evolutiva, Pediatric Clinic S. Maggiore, University of Bari; and ^cAllergy and Respiratory Diseases, Department of Internal Medicine, University of Genoa, Italy. E-mail: passalacqua@unige.it.

Disclosure of potential conflict of interest: The authors have declared that they have no conflict of interest.

REFERENCES

- Kumar S. Vernal keratoconjunctivitis: a major review. *Acta Ophthalmol* 2009;87:133-47.
- Bonini S, Coassin M, Aronni S, Lambiase A. Vernal keratoconjunctivitis. *Eye* 2004;18:345-51.
- Leonardi A, Busca F, Motterle L, Cavarzeran F, Fregona IA, Plebani M, et al. Case series of 406 vernal keratoconjunctivitis patients: a demographic and epidemiological study. *Acta Ophthalmol Scand* 2006;84:406-10.
- Bousquet J, Kalthaev N, Cruz AA, Denburg J, Fokkens W, Togias A, et al. Allergic Rhinitis and its Impact on Asthma. *Allergy* 2008;63(suppl):1-13.
- Bonini S, Sacchetti M, Mantelli F, Lambiase A. Clinical grading of vernal keratoconjunctivitis. *Curr Opin Allergy Clin Immunol* 2007;7:436-41.
- Gelardi M, Maselli Del Giudice A, et al. Non-allergic rhinitis with eosinophils and mast cells (NARESMA) constitutes a new severe nasal disorder. *Int Journal Immunopathol Pharmacol* 2008;23:325-31.
- Gelardi M, Russo C, Fiorella ML, Fiorella R, Canonica GW, Passalacqua G. When allergic rhinitis is not only allergic. *Am J Rhinol Allergy* 2009;23:312-5.
- Bielory L. Allergic and immunologic disorders of the eye, part II: ocular allergy. *J Allergy Clin Immunol* 2000;106:1019-32.
- Anderson DF, Zhang S, Bradding P, McGill JJ, Holgate ST, Roche WR. The relative contribution of mast cell subsets to conjunctival TH2-like cytokines. *Invest Ophthalmol Vis Sci* 2001;42:995-1001.
- Uchio E, Ono SY, Ikezawa Z, Ohno S. Tear levels of interferon-gamma, interleukin (IL) -2, IL-4 and IL-5 in patients with vernal keratoconjunctivitis, atopic keratoconjunctivitis and allergic conjunctivitis. *Clin Exp Allergy* 2000;30:103-9.
- Ciprandi G, Marseglia G, Klersey A, Tosca M. Relationships between allergic inflammation and nasal airflow in children with persistent allergic rhinitis due to mite sensitization. *Allergy* 2005;60:957-60.

doi:10.1016/j.jaci.2009.10.058

S2554X mutation in the filaggrin gene is associated with allergen sensitization in the Japanese population

To the Editor:

Atopic diseases such as atopic dermatitis (AD) and allergic rhinitis are some of the most common diseases in developed societies, and the number of patients with these diseases is increasing. These diseases are caused by interactions between genetic and environmental factors; some patients develop various atopic diseases concurrently, whereas others show a gradual progression from one manifestation of allergy to the next (atopic march),¹ thereby indicating common genetic/environmental features among atopic diseases.

Skin barrier dysfunction may contribute to the allergen penetration responsible for AD and predate the development of asthma and allergic rhinitis.² Filaggrin (filament-aggregating protein; FLG) has been reported to play an important role in skin-barrier formation and hydration. FLG aggregates the keratin cytoskeleton to facilitate the collapse and flattening of keratinocytes in the outermost skin layer. Null mutations in *FLG* are associated with AD in various populations, and some mutations showed associations with rhinitis and allergen sensitization in white pediatric populations.³ In a recent study, *Flg*-deficient mice showed a predisposition to sensitization after percutaneous exposure to an allergen and developed cutaneous inflammatory infiltration and allergen-specific immune responses after allergen sensitization.⁴

TABLE I. Characteristics of the study population (1499 subjects)

Characteristic	
Sex (male:female)	466:1033
Age (y), mean ± SD	32.3 ± 9.7
Asthma (current and past)	104/1093
Allergic rhinitis	575/1093
Sensitization	1014/1499
Total IgE (IU/mL), geometric mean	65.6 (range, <5-24,000)
Specific IgE (U _A /mL)	Prevalence (range, U _A /mL)
Mite	39% (<0.34-100)
Japanese cedar	62% (<0.34-100)
<i>Dactylis glomerata</i>	26% (<0.34-100)
<i>Ambrosia artemisiifolia</i>	12% (<0.34-32)
<i>Candida albicans</i>	6.5% (<0.34-35.8)
<i>Aspergillus</i>	3.3% (<0.34-9.1)

Total IgE values of <5 IU/mL have been considered as 0.1 IU/mL for the sake of calculations. The prevalence of specific IgE was calculated as the proportion of subjects with specific IgE titer of >0.70 U_A/mL.

We previously reported that the null allele of *FLG* showed statistically significant association with AD, and this association was stronger in the Japanese patients with the only-AD phenotype—that is, patients with AD without other atopic diseases.⁵ However, the effects of *FLG* null mutations on other atopic conditions have not been investigated in Asian populations. In the current study, we genotyped 4 *FLG* null mutations in the Japanese general population and studied the association between these mutations and atopic phenotypes.

Between 2003 and 2007, 1575 hospital workers and university students were invited to participate in this study. All the participants were of Japanese origin and were residents of Fukui prefecture, Japan. The characteristics of the study population are shown in Table I. Asthma was diagnosed on the basis of whether patients answered that they had ever been diagnosed with asthma by a doctor. Allergic rhinitis was diagnosed on the basis of a positive history of rhinitis during the pollen season and/or all seasons, and high levels of allergen-specific IgE antibodies in the serum (RAST score ≥class 2). Total and specific IgE (produced in response to Japanese cedar, *Dermatophagoides*, *Dactylis glomerata*, *Ambrosia artemisiifolia*, *Candida albicans*, and *Aspergillus*) were measured by using the CAP-RAST method (Pharmacia Diagnostics AB, Uppsala, Sweden), and positive allergic sensitization was defined if the levels of 1 or more specific IgE molecules were greater than or equal to 0.70 IU/mL (class2). All the participants gave their written informed consent to participate in the study. The study was approved by the ethical committees of the University of Tsukuba and the University of Fukui, Japan.

Genomic DNA was extracted from whole-blood samples by using a DNA-isolation kit (QuickGene-810; Fuji, Tokyo, Japan). The 3321delA genotype was determined by sizing a fluorescently labeled PCR fragment on an Applied Biosystems 3100 DNA Sequencer (Applied Biosystems, Foster City, Calif) as described previously.⁶ S2554X, S2889X, and S3296X were genotyped on TaqMan Assay-by-Design system for single nucleotide polymorphism genotyping (Applied Biosystems). The accuracy of genotyping was confirmed by using direct sequences/restriction fragment length polymorphism analysis⁷ of samples obtained from all carriers and selected noncarriers of the null mutations.